

Treatment of the Complex Idiopathic Clubfoot

*Ignacio V. Ponseti, MD**; *Miroslav Zhivkov, MD†*; *Naomi Davis, FRCSEd‡*;
Marc Sinclair, MD§; *Matthew B. Dobbs, MD||*; and *Jose A. Morcuende, MD, PhD**

Treatment with the Ponseti method corrects congenital idiopathic clubfeet in the majority of patients. However, some feet do not respond to the standard treatment protocol. We describe the characteristics and treatment results of these complex idiopathic clubfeet. We identified 50 patients (75 clubfeet) from 762 consecutive patients treated at five institutions. Clinically, complex clubfeet were defined as having rigid equinus, severe plantar flexion of all metatarsals, a deep crease above the heel, a transverse crease in the sole of the foot, and a short and hyperextended first toe. The Achilles' tendon was exceptionally tight and fibrotic up to the middle of the calf. Correction was achieved in all patients by modifying the Ponseti manipulation and casting technique. Correction required an average of five casts (range, 1–10 casts). Two patients (4%) not initially recognized as having complex clubfeet had a posterior release with tendo Achillis lengthening. There were seven relapses that responded to casting. Three patients had a second tenotomy. Modifying the treatment protocol for complex clubfeet successfully corrected the deformity without the need for extensive corrective surgery.

Level of Evidence: Therapeutic study, Level IV (case series). See the Guidelines for Authors for a complete description of levels of evidence.

Received: March 11, 2005

Revised: September 23, 2005; January 29, 2006; February 10, 2006; April 24, 2006

Accepted: May 17, 2006

From the *Department of Orthopaedic Surgery and Rehabilitation, University of Iowa, Iowa City, IA; the †University Hospital "Saint Anna," Varna, Bulgaria; ‡Booth Hall Children's Hospital, Manchester, UK; the §Altonaer Kinderkrankenhaus, Hamburg, Germany; and the ||Department of Orthopaedic Surgery, Washington University, St. Louis, MO.

Each author certifies that he or she has no commercial associations (eg, consultancies, stock ownership, equity interest, patent/licensing arrangements, etc) that might pose a conflict of interest in connection with the submitted article.

Each author certifies that his or her institution has approved the human protocol for this investigation and that all investigations were conducted in conformity with ethical principles of research, and that informed consent was obtained.

Correspondence to: Jose A. Morcuende, MD, PhD, Department of Orthopaedic Surgery and Rehabilitation, 200 Hawkins Drive, Iowa City, IA 52242. Phone: 319-384-8041; Fax: 319-353-7919; E-mail: jose-morcuende@uiowa.edu.

DOI: 10.1097/01.blo.0000224062.39990.48

Congenital idiopathic clubfoot is a deformity typically occurring in an otherwise healthy child. The most recent reports using the Ponseti method showed excellent corrections in the majority of patients.^{2,3,6,7,9–11,14,15} Most clubfeet correct with four to six manipulations followed by plaster cast applications by skillful orthopaedists. However, a small percentage of clubfeet are very severe and difficult to treat. They have been called very severe,¹² stiff-stiff,⁵ and teratogenic⁸ and typically score 10 on the Carroll severity scale.¹ Numerous surgeons have performed complete, plantar, lateral, medial, and posterior releases with poor results.^{1,4,8} We have corrected these feet using our standard technique with eight to 10 plaster casts. (A video of our standard technique is available online. Supplemental materials are available via the Article Plus feature at www.corronline.com. You may locate this article then click on the Article Plus link on the right.) Relapses have been frequent, however, leading us to perform subsequent anterior tibial transfer to the third cuneiform.

There are a small number of clubfeet refractory to the usual corrective manipulation and casting as Turco observed.¹⁶ He said they "... respond altogether differently to both operative and non-operative treatment and that early surgery [results] in a grotesquely deformed foot." He called these feet atypical and warned against surgery. Some of these feet may appear typical when the infant is born, with the forefoot and toes pointing to the other foot. Others are in very severe supination with the forefoot and toes pointing to the thigh of the same leg. The calf muscles are small and the tendo Achillis is long, wide, and very tight, pulling the calcaneus into severe equinus causing a deep crease above the heel. The forefoot is in adduction and all the metatarsals are in plantar flexion, causing a severe cavus and a deep crease across the sole of the foot.

Although the forefoot adduction can be corrected easily with one or two plaster casts, the metatarsals remain in severe plantar flexion. Additional attempts to correct the hindfoot varus by abducting the foot deformity pushes the metatarsals and toes into additional flexion and abduction resulting in a grotesque deformity. We suspect the abnor-

malities affecting the calf muscles and the posterior ligaments of the ankle extend to the deep intrinsic plantar muscles and ligaments of the foot. We think only if the deformity is recognized as such can it be corrected with modifications in our usual protocol.

We therefore questioned whether our modified treatment regimen would result in correction and maintenance of the correction for these complex clubfeet.

MATERIALS AND METHODS

We retrospectively reviewed 762 patients with congenital idiopathic clubfoot treated at our five institutions from October 1992 to February 2004. Of these 762 patients, 50 (6.5%) with 75 clubfeet were considered to have complex clubfeet because they were in severe equinus and supination, short and stubby, with the adducted metatarsals in plantar flexion and deep creases across the sole of the foot and above the heel (Fig 1). Thirty-one patients (68%) were boys. Thirteen patients (22%) had a positive family history of idiopathic clubfoot. The average age of the patients at presentation to our clinics was 3 months (range, 1 week–9 months). Nineteen patients were treated from the start at our institutions, and 31 patients (62%) had plaster-cast treatment (we do not know the precise techniques of manipulation or casting) elsewhere before their initial visit. We excluded patients with arthrogryposis, syndromic, or neuromuscular clubfeet. No patients were lost to followup. The average age at last followup for all patients with complex clubfeet was 23 months (range, 6–46 months). Institutional Review Board approval was obtained at all five institutions.

Initially, the lateral malleolus in all feet was prominent. The calcaneus was in 50° to 70° plantar flexion. The forefoot was severely adducted. All metatarsals were in plantar flexion, making the foot look short and arched downward. The anterior tuberosity of the calcaneus was prominent dorsally and in contact with a small, barely identifiable head of the talus. The navicular

was in contact with the medial malleolus. There was minimal motion in the severely supinated tarsal joints. The gastrosoleus was small and bunched up in the upper third of the leg. The tendo Achillis was long and wide, inserting into the severely plantar flexed calcaneus.

The 31 patients initially treated by other orthopaedists had a median of nine (range, 3–20) plaster casts before referral, some below the knee, others a combination of below and above the knee. Many of the casts had slipped down completely or partially to the middle or tip of the crowded toes, causing edema, wrinkles, and sores on the dorsal skin of the foot. The big toe, often in hammertoe position, was short; the other toes were in some flexion and the whole foot was grotesquely stunted. In unilateral cases, the involved foot usually was shorter (estimated 1.5–2 cm) than the normal foot. Eleven of these patients (22%) had a percutaneous tendo Achillis tenotomy, and three patients had a tendo Achillis lengthening.

Radiographs were not routinely obtained. However, the parents of 16 patients brought radiographs performed at their local institutions. The calcaneus and the talus were in severe plantar flexion. In most cases, the talocalcaneal angle was parallel in the AP and lateral views. The cuboid was displaced medially and all the metatarsals were in severe plantar flexion, more so the first metatarsal. We obtained AP and lateral radiographs (without forced dorsiflexion) for nine patients because of questions regarding abnormal hyperabduction of the forefoot (there was usually a skin fold in the lateral aspect of the midfoot). The metatarsals were hyperabducted at the Lisfranc line with as much as 90° plantar flexion (Fig 2). No radiographs were obtained at the latest followup.

We modify our usual approach in these complex feet. Correction required precise identification of the subtalar joint. The forefoot had to be grasped with one hand while feeling the malleoli from the front with the thumb and index finger of the other hand (Fig 3A). The thumb and index finger then were moved forward to clasp the head of the talus and feel the navicular on one side and the anterior tuberosity of the calcaneus on the other side. Motion at the subtalar joint could be felt when the foot was slowly abducted, and the anterior tuberosity of the calcaneus moved laterally under the head of the talus (Fig 3B). In these severe complex clubfeet, this motion was minimal at first but could be felt after removal of the second or third plaster cast. Correction also required clear identification of the head of the talus, which is difficult to locate because it is less prominent than the anterior tuberosity of the calcaneus. To make certain of the position of the talar head during stretching and while applying the cotton and plaster cast bandage over the foot, the index finger should rest over the posterior aspect of the lateral malleolus while the thumb of the same hand applies counter pressure over the lateral aspect of the head of the talus (Fig 4), not on the very prominent tuberosity of the calcaneus. Adduction of the forefoot was corrected easily after one or two manipulations and plaster cast applications (changed weekly). However, the metatarsals remained in severe plantar flexion and the hindfoot in severe equinus. The foot was arched downward and often slipped up inside the cast. The toes gradually disappeared and the edematous dorsal skin folded downward along with the cast while the

Fig 1

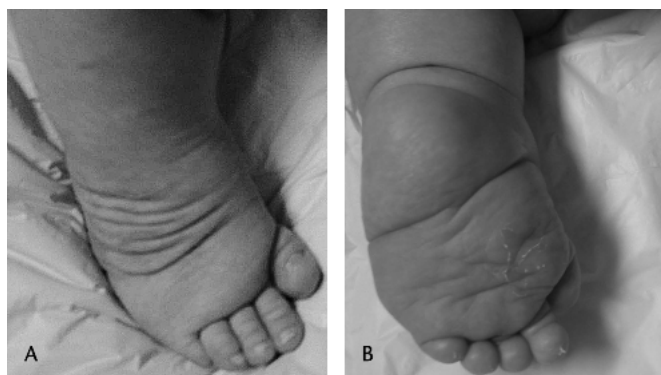
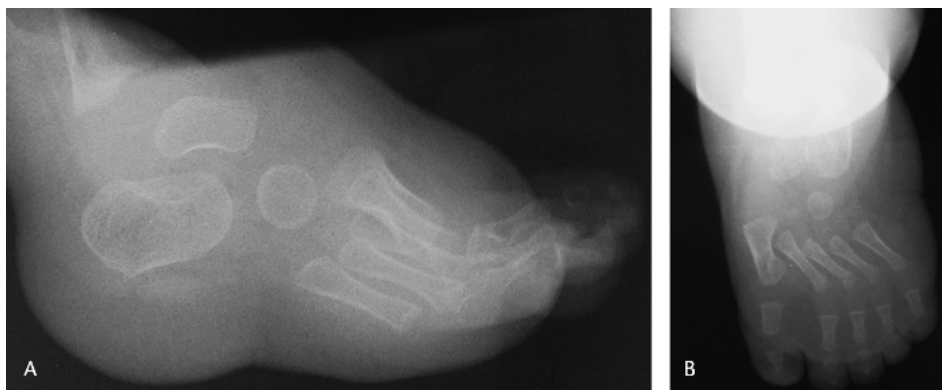
Fig 1A–B. The photographs show a 3-month-old infant with complex clubfoot. (A) Complex clubfeet have a characteristic rigid equinus and a short and hyperextended first toe. (B) Also present are a transverse crease in the sole of the foot and another deep crease above the heel.

Fig 2 A–B. The radiographs show a 5-month-old infant with complex clubfoot. (A) The foot is in equinus, and all the metatarsals are in severe plantar flexion. (B) There is excessive abduction of the metatarsals caused by faulty manipulation and casting.



deformity worsened. To prevent slippage of the plaster cast, hyperflexion of the metatarsals and rigid equinus were corrected simultaneously by grasping the foot by the ankle with both hands while the thumbs under the metatarsals pushed the foot into dorsiflexion as an assistant stabilized the knee in flexion. Care was taken not to hyperabduct the metatarsals and hindfoot (Fig 5). To immobilize the foot in the corrected position, a plaster splint was applied over the calf, heel, and sole, reinforced by a well-molded plaster bandage. Similarly, the knee was immobilized in at least 110° flexion by applying a plaster splint in front of the knee, reinforced by a plaster bandage around the thigh, avoiding excessive plaster behind the knee and in front of the ankle. Patients required an average of five casts (range, 1–10 casts) for full correction. All patients had a tendo Achillis tenotomy to correct equinus.

In most patients, the tendo Achillis was sectioned percutaneously before application of the last plaster cast. The tenotomy always was performed 1.5 cm above the posterior skin crease of

the heel, avoiding damage to the calcaneus posterior tuberosity (which is usually very high given the severe equinus). In previously treated patients, a second tenotomy was not performed if the foot could be dorsiflexed a few degrees above neutral (5°). The foot should not be abducted beyond 40°. When hyperflexion of the metatarsals was improved in seven patients, but the equinus still was unyielding, we sectioned the patient's tendo Achillis under local anesthesia and changed the cast weekly (one to four times) until we obtained abduction of the foot (as much as 40°) and dorsiflexion (at least 5°). Final mean ankle dorsiflexion at the end of the correction was 10° (range, 5°–20°).

Well-molded shoes attached in 40° outer rotation to a foot abduction bar are indispensable to prevent relapse in short, stubby complex clubfeet. We have used a new brace that has a soft, premolded, and well-adjusted sandal with three straps, which prevents slippage of the foot (Fig 6). This brace is well tolerated by patients

We determined the following: age of the patient at the first visit, previous treatment and type of treatment before referral,

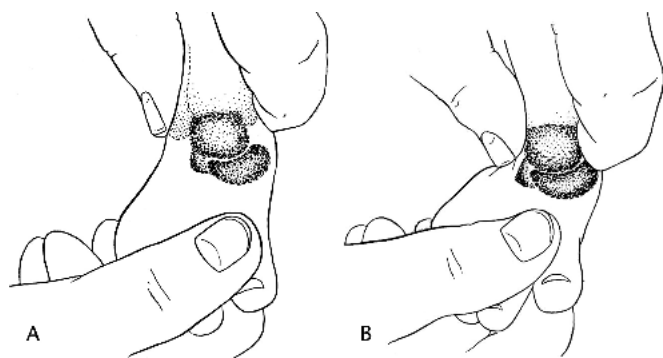


Fig 3A–B. An illustration shows the position of the talus and motion of the subtalar joint. (A) They are identified by grasping the forefoot with one hand while the malleoli are felt from the front with the thumb and index finger of the other hand. (B) The thumb and index finger then slide down to clasp the head of the talus, and to feel the navicular on one side and the anterior tuberosity of the calcaneus on the other side. Motion at the subtalar joint can be felt when the foot is moved in to abduction.

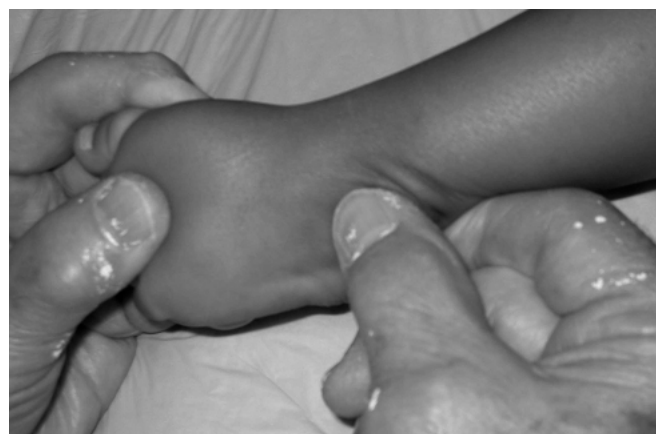

Fig 4. A photograph shows the hand position for manipulating and holding a complex clubfoot. The index finger should rest over the posterior aspect of the lateral malleolus while the thumb of the same hand applies counter pressure over the lateral aspect of the head of the talus.

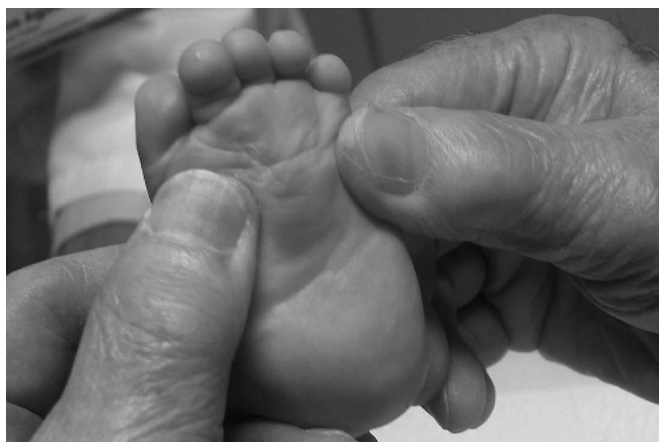

Fig 5. A photograph shows a modification of the manipulation technique for treatment of complex clubfoot. All metatarsals are extended simultaneously with both thumbs while the forefoot is mildly abducted. The heel also is dorsiflexed and slightly abducted.

number of plaster casts, previous tendoachilles tenotomy or lengthening, correction of the deformity components, degree of ankle dorsiflexion after tenotomy, need for a second percutaneous tendo Achillis tenotomy, complications with casting, compliance with the foot abduction brace (assessed based on parents' reports), the need for extensive soft tissue releases, and the occurrence and treatment of relapses.

RESULTS

At the last followup, all feet were well corrected with mean ankle dorsiflexion of 15° (range, 10° – 25°). There was a minimal cavus deformity in six patients, which was passively corrected. The skin changes completely resolved except for the remaining, but improved, plantar crease in 10 patients (Fig 7).

Seven patients (14%) had a relapse after initial successful treatment, and two patients had a second relapse. The average time from correction until diagnosis of the first relapse was 1.5 months (range, 2 weeks–3 months). Second relapses were observed 3 and 6 months after the first relapse. All relapses were related to problems with shoe fit with the standard foot abduction brace (most parents reported difficulties keeping the shoes on, with subsequent slippage of the foot and development of skin lesions). Relapses were treated with a second series of manipulations and casting (one cast in one patient, two casts in three patients, three casts in one patient, and four casts in one patient) changed every 2 weeks. Three patients (one patient with the first relapse, and two patients with the second relapses) had a second tendo Achillis tenotomy owing to recurrent equinus. No relapses occurred after using a new, premolded foot-ankle abduction brace (Fig 6). None of these seven patients have had anterior tibial tendon transfer.

Two patients, who were not recognized initially as having complex clubfeet, had release of the posterior ligaments of the ankle and subtalar joints in addition to tendo Achillis lengthening. Since the modified treatment protocol has been used, no other patients have required surgical releases.

Eleven patients (22%) had complications including erythema, slight swelling of the forefoot and toes, mild rocker-bottom deformity, midfoot hyperabduction, or repeated downward cast slippage. No infections or profuse bleeding were observed after the tenotomy.

DISCUSSION

Orthopaedists familiar with the treatment of congenital clubfoot know a small percentage of clubfeet are stiff and resistant to manipulation.^{10–13} However, the tissues usu-

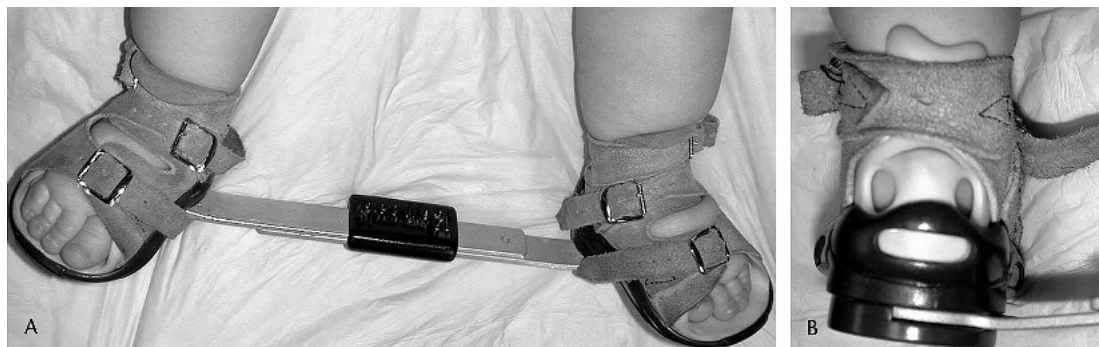

Fig 6A–B. A photograph shows the premolded foot-ankle abduction brace for treatment of complex clubfeet. (A) There are three straps to hold the foot firmly in the sandal. (B) Two openings at the heel allow the parents to see that the hindfoot is correctly placed.

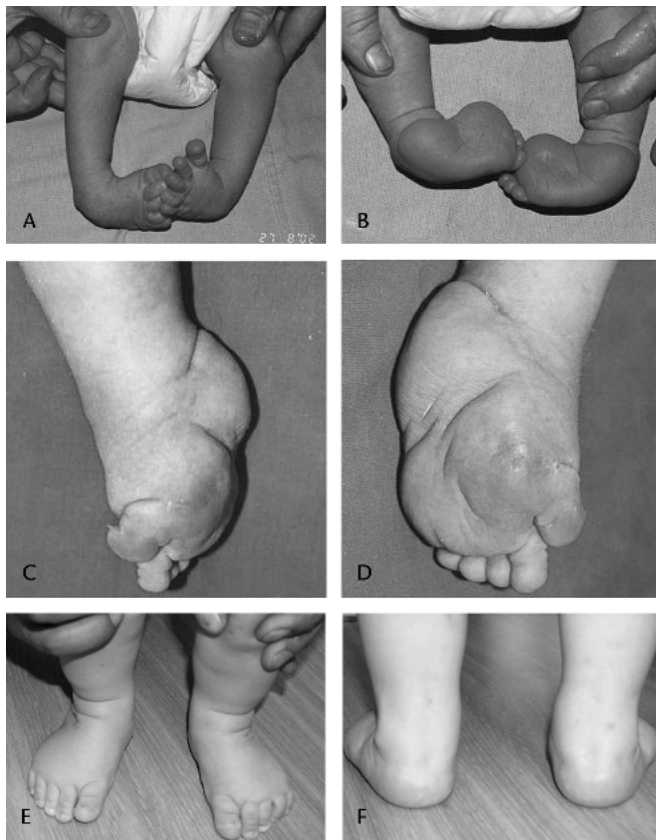


Fig 7A–F. Photographs show a newborn with bilateral clubfeet. (A) The first toe is of normal length, and (B) the medial crease does not reach the outside border of the foot. After seven casts, no additional correction was obtained in the (C) right or (D) left foot. The feet had a characteristic severe complex foot deformity. The modified Ponseti manipulation and casting treatment was performed. Clinical photographs taken at 12 months show the feet look normal from the (E) front and (F) back and the deformity has been corrected.

ally soften after three to four casts, and the feet eventually are corrected with five or six more casts.

Our study has several limitations. First, we used no severity classification system because most patients were treated previously and referred for additional treatment. Therefore, we have no information regarding initial severity. We do not know the precise number or sorts of manipulations and castings performed because we relied mainly on information from the parents. Therefore, we can draw no conclusions regarding whether the treatment failed owing to the feet or to the treatment. Although this limits comparability with treatments in other series, all patients either initially had severe, complex clubfeet (those treated in our institution) or met our criteria for complex clubfoot after failed treatment elsewhere. We had no radiographic followup. This limits comparison of bony cor-

rection in series with routine radiographs, but not clinical correction. We have found that the foot's shape, length, and dorsiflexion improves a few months after correction. In addition, the subtalar joint motion also normalizes, therefore, we have not found it necessary to obtain radiographs. Finally, the length of followup was only 2 years. Although this followup may not be long enough to assess relapses, the natural history of relapses in clubfoot is that most (80%) will happen during the first 2 years of life. Because the foot normalizes a few months after correction, we think it is unlikely that we will observe a greater rate of relapses in these complex clubfeet.

The complex clubfoot is short and stubby. The calf muscles are small and the tendo Achillis is long, wide, and tight. The hindfoot is in severe equinus and varus. The forefoot is adducted and all metatarsals are in severe plantar flexion. There is a deep crease across the sole of the foot and another above the heel. The severe equinus is concurrent with severe plantar flexion of the metatarsals and apparent shortening of the foot and toes. Such deformity may be attributable to shortening and tightness of the deep plantar intrinsic muscles of a similar nature to the changes observed in the calf muscles. Severe fibrosis in the quadratus plantae inserted into the long toe flexors explains the persistent hyperabduction of the metatarsals after faulty manipulations. In most clubfeet there is increased fibrous tissue in the muscles, fasciae, and ligaments, mainly in the gastrosoleus, posterior tibial, long toe flexors, and the posterior ankle and medial tarsal ligaments.¹⁴ In the complex clubfoot, it is the gastrosoleus and the plantar intrinsic muscles and ligaments that are more severely involved. The medial ligaments and tendons of the foot can be stretched easily, but the cavus and the equinus strongly resist correction. The grotesque deformity results from attempts to hyperabduct the midfoot and forefoot, as is done in typical clubfeet.

The deformity is difficult to treat because although the forefoot adduction is corrected easily after the first or second manipulation and casting, the metatarsals remain in stiff plantar flexion and the calcaneus remains fixed in equinus. Additional attempts to correct the heel varus by abducting the foot causes hyperabduction of the severely plantar-flexed metatarsals. Because of the rigid flexion of the heel and metatarsals, the plaster cast easily slips off, making the deformity worse and damaging the edematous skin of the dorsum of the foot. To correct heel varus in complex clubfeet, the hindfoot is abducted with counter pressure applied not only to the talar head but also to the lateral malleolus. The forefoot should not be abducted beyond its normal alignment. Once the heel varus is corrected, the flexed forefoot and the equinus are corrected simultaneously by forcefully dorsiflexing the metatarsals with both thumbs while applying a plaster cast reinforced

by a posterior slab. To prevent the plaster cast from slipping, the knee is immobilized in at least 110° flexion. A tenotomy is performed before applying the last plaster cast unless it needs to be done to facilitate correction of an unyielding equinus.

In our experience, once a complex clubfoot is corrected, the rigidity of the soft tissues lessens, the skin creases and puffiness disappear, and the foot develops normally.

References

1. Carroll NC. Preoperative Clinical Assessment of Clubfoot. In: Simons GW, ed. *The Clubfoot: The Present and a View of the Future*. New York, NY: Springer-Verlag; 1994:97-98.
2. Chotel F, Parot R, Durand JM, Garnier E, Hodgkinson I, Berard J. Initial management of congenital varus equinus clubfoot by Ponseti's method. *Rev Chir Orthop Reparatrice Appar Mot*. 2002;88:710-717.
3. Colburn M, Williams M. Evaluation of the treatment of idiopathic clubfoot by using the Ponseti method. *J Foot Ankle Surg*. 2003;42:259-267.
4. Dimeglio A. Classification of talipes equinovarus. In: Simons GW, ed. *The Clubfoot: The Present and a View of the Future*. New York, NY: Springer-Verlag; 1994:92-93.
5. Dimeglio A, Bensahel H, Souchet P, Mazeau P, Bonnet F. Classification of clubfoot. *J Pediatr Orthop*. 1995;4:129-136.
6. Dobbs MB, Rudzki JR, Purcell DB, Walton T, Porter KR, Gurnett CA. Factors predictive of outcome after use of the Ponseti method for the treatment of idiopathic clubfeet. *J Bone Joint Surg*. 2004;86:22-27.
7. Goksan SB. Treatment of congenital clubfoot with the Ponseti method. *Acta Orthop Traumatol Turc*. 2002;36:281-287.
8. Goldner JL, Fitch RD. Classification and evaluation of congenital talipes equinovarus. In: Simons GW, ed. *The Clubfoot: The Present and a View of the Future*. New York, NY: Springer-Verlag; 1994:120-139.
9. Herzenberg JE, Radler C, Bor N. Ponseti versus traditional methods for idiopathic clubfoot. *J Pediatr Orthop*. 2002;22:517-521.
10. Lehman WB, Mohaideen A, Madan S, Scher DM, Van Bosse HJ, Iannacone M, Bazzi JS, Feldman DS. A method for the early evaluation of the Ponseti (Iowa) technique for the treatment of idiopathic clubfoot. *J Pediatr Orthop B*. 2003;12:133-140.
11. Morcuende JA, Dolan LA, Dietz FR, Ponseti IV. Radical reduction in the rate of extensive corrective surgery for clubfoot by using the Ponseti method. *Pediatrics*. 2004;113:376-380.
12. Pandey S, Pandey AK. Clinical classification of congenital clubfeet. In: Simons GW, ed. *The Clubfoot: The Present and a View of the Future*. New York, NY: Springer-Verlag; 1994:91-92.
13. Perry J. Anatomy and biomechanics of the hindfoot. *Clin Orthop Relat Res*. 1983;177:9-15.
14. Ponseti IV. *Congenital Clubfoot: Fundamentals of Treatment*. Oxford, UK: Oxford University Press; 1996.
15. Ponseti IV, Smoley EN. Congenital clubfoot: the results of treatment. *J Bone Joint Surg Am*. 1963;45:261-275.
16. Turco V. Recognition and management of the atypical idiopathic clubfoot. In: Simons GW, ed. *The Clubfoot: The Present and a View of the Future*. New York, NY: Springer-Verlag; 1994:76-77.